



PATIENT

Max Bretz

SPECIES

Canine

BREED

Doberman Mix

SEX

Male Neutered

AGE

7 years

WEIGHT

108lbs

INTERPRETED BY

Maggie Machen Lamy,
DVM, DACVIM
(Cardiology)

IMAGING PERFORMED BY

Dana Alterman,
RDCS, LVT

HOSPITAL NAME

Eubank Animal Clinic

REFERRING VET

Dr. Long

INVOICE

28045

DATE

1/2/23

PRESENTING CLINICAL SIGNS

History: Recheck echo. Assess prior to dental.

-Current medications: Taurine, Pimobendan and Enalapril.

-Pertinent previous echo findings (12/2021 Antech): Moderate LAE. LA: 4.17cm, LA/Ao: 1.7 (short axis), LVIDd: 4.6cm, FS 19% (from 2D image), and LV walls appear thin.

ELECTROCARDIOGRAPHIC FINDINGS *Note: Single lead ECGs are evaluated as a rhythm strip. Morphology/MEA cannot be definitively commented on.

A single lead ECG is available; 50mm/s, 20mm/mV. The average heart rate is 100bpm (range 88-120bpm). The rhythm is sinus in origin, with a p for every QRS complex and vice versa. The P and QRS morphologies are positive. No ectopic beats, pauses or other dysrhythmias observed. ECG diagnosis: Normal sinus rhythm with respiratory variation.

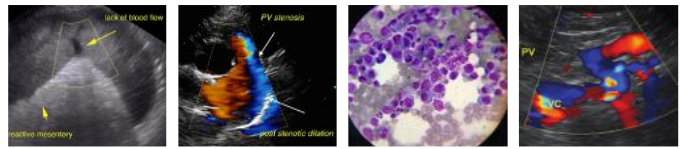
ECHOCARDIOGRAM FINDINGS

2D, m-mode, color flow and doppler imaging is available. The left ventricular is normal in diastole with an increased systolic dimension. Mild to moderate systolic dysfunction. Mildly decreased LV wall thickness and increased sphericity. Mild left atrial enlargement. The mitral valve appears thickened with no obvious prolapse into the left atrial lumen. The tricuspid valve appears normal in form and function. No right heart enlargement. The aortic and pulmonic valves appear normal in morphology and mobility. No AI or PI. Normal LVOT velocity. No pericardial or pleural effusion noted. No obvious cardiac tumors.

CARDIAC CHART

CANINE CARDIAC PARAMETERS	MR VMAX (m/s)	TR VMAX (m/s)	LA/AO (Boon method)	LA/AO (Heart Base; Swe)	FS (%)	EF (%)	EPSS (cm)
NORMAL PARAMETER	4.5-5.5	<2.7	1.3	<1.6	28-40	40-100	<0.6
PATIENT	NM	NM	NM	1.66	22	40	NM
CANINE CARDIAC PARAMETERS	HR (BPM)	AV VMAX (m/s)	PV MAX (m/s)	BODY WEIGHT (kg)	LA 2D short axis Base view (cm)	LVIDd Avg; 2D and m-mode short axis (cm)	LVIDs Avg; 2D and m-mode short axis (cm)
NORMAL PARAMETER	50-100	0.7-1.7	0.7-1.6	BELOW	BELOW	BELOW	BELOW
PATIENT	NM	1.1	NM	7.0	4.0	4.4	3.4
*Normal chamber parameters expressed as a mean value (SD)				3	1.27 (5.3)	2.46 (2.46)	1.36 (5.5)
BODY WEIGHT DEPENDENT PARAMETERS				5	1.40 (4.5)	2.74 (5.2)	1.60 (4.7)
*Note: All measurements based upon multi-modal images and methods. An average value is reported.				10	1.50 (3.8)	3.27 (3.5)	2.06 (3.1)
				15	1.83 (2.0)	3.71 (2.4)	2.43 (2.1)
				20	2.02 (1.9)	4.14 (2.2)	2.80 (2.0)
				25	2.18 (2.4)	4.48 (2.9)	3.10 (2.5)
				30	2.33 (3.3)	4.83 (3.9)	3.39 (3.4)
				35	2.48 (4.3)	5.17 (5.0)	3.69 (4.5)
				40	2.62 (5.2)	5.48 (6.1)	3.96 (5.4)
				50	2.88 (7.1)	6.07 (8.3)	4.46 (7.4)

Adapted from June Boon, Veterinary Echocardiography, 1998
Rishniw M and Hollis NE, J Vet Intern Med 2000; 14:429-435
Hansson et al, Vet Rad and Ultrasound 2002
Bonagura et al. Echocardiography: principles of interpretation, Vet Clin North Am 15:1177, 1995



PATIENT

Max Bretz

SPECIES

Canine

BREED

Doberman Mix

SEX

Male Neutered

AGE

7 years

WEIGHT

108lbs

INTERPRETED BY

Maggie Machen Lamy,
DVM, DACVIM
(Cardiology)

IMAGING PERFORMED BY

Dana Alterman,
RDCS, LVT

HOSPITAL NAME

Eubank Animal Clinic

REFERRING VET

Dr. Long

INVOICE

28045

DATE

1/2/23

INTERPRETATION OF THE FINDINGS & FURTHER RECOMMENDATIONS

Compared to the prior study, findings appear similar. The LV is normal in diastole; however, an increased systolic dimension is noted with overall dysfunction. The LA is mildly enlarged, indicating low risk for complication at this time. No additional issues are identified. The ECG is unremarkable with a normal sinus rhythm.

Systolic dysfunction can be primary in nature (DCM) or secondary to taurine deficiency, certain drugs such as Doxorubicin, myocarditis, hypothyroidism, tachycardia-induced cardiomyopathy, or infiltrative disease such as lymphoma. In a senior Doberman, primary disease is suspected. Prognosis is guarded long term with risk for complications going forward.

Recommend continue Pimobendan, ACE-I and Taurine in this case as below. No additional medications are indicated at this time.

Monitor for development of a cough, labored breathing, exercise intolerance or collapse episodes in the future. Monitoring of sleeping breathing rates at home is recommended to screen for progression in the future. Mild activity restriction is advised. Omega fatty acid supplementation and mild salt restriction may be of some long-term benefit.

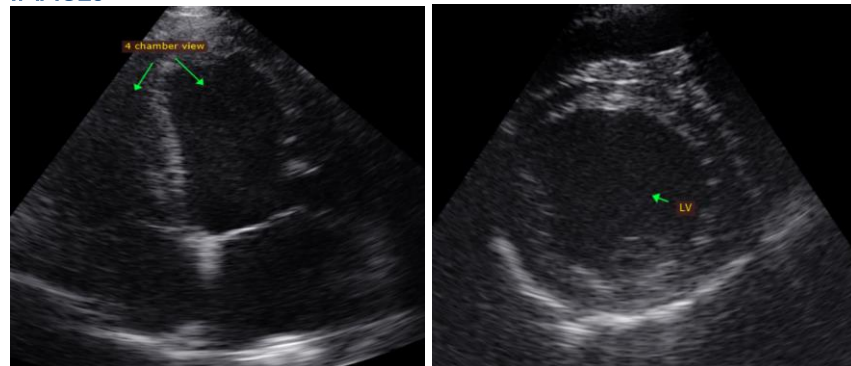
Anesthetic risk is considered mild if needed. Cardiac protective drug choices (opioid/benzodiazepine premedication, propofol or alfaxalone induction, isoflurane gas) are recommended. Pre-oxygenate for 5-10 minutes prior to induction. Monitor for arrhythmias, hypotension, and hypoxia both intra and post-operatively and intervene as necessary. Mild IV fluid restriction is recommended to avoid fluid overload. Avoid heart rate stimulating drugs such as atropine unless clinically indicated.

PLAN

Administer Pimobendan 0.25-0.3mg/kg PO q12h. Administer taurine supplement 1000mg PO q12h. Administer ACE-I 0.5mg/kg PO q12h (pending BP assessment).

A recheck echocardiogram is recommended in 6 months to assess for progression, sooner if clinical signs arise.

IMAGES





PATIENT

Max Bretz

SPECIES

Canine

BREED

Doberman Mix

SEX

Male Neutered

AGE

7 years

WEIGHT

108lbs

INTERPRETED BY

Maggie Machen Lamy,
DVM, DACVIM
(Cardiology)

**IMAGING
PERFORMED BY**

Dana Alterman,
RDCS, LVT

HOSPITAL NAME

Eubank Animal Clinic

REFERRING VET

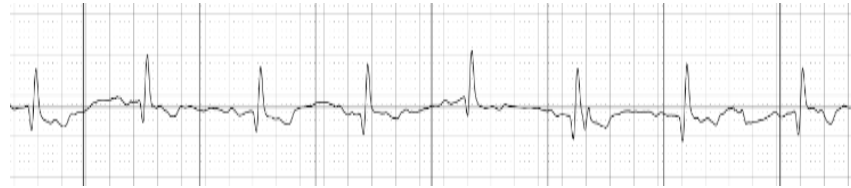
Dr. Long

INVOICE

28045

DATE

1/2/23



The information and recommendations provided are based on the images presented by the referring veterinarian. No evaluation can be communicated regarding pathology that was not visible in the image/video clips provided.

Thank you for this referral. This report was generated using transcription software, and minor dictation errors may be present. If the clinical or image interpretation does not parallel your findings or if I can be of any further assistance, please contact me.

Maggie Machen Lamy, DVM
Diplomate of the American College of Veterinary Internal Medicine (Cardiology)
info@sonopath.com